

Intra-articular replacement of a ruptured cranial cruciate ligament in dogs using a synthetic graft

*Krister Julinder, DVM
Söderköpings Djurklinik, Arthro clinic, Söderköping, Sweden*

Abstract

Background A ruptured cranial cruciate ligament results in an unstable joint and secondary inflammation which, over time, often leads to the development of progressive osteoarthritis. The aim of this report is to describe the surgical technique and the clinical outcome in dogs treated with a synthetic graft in the replacement of a ruptured cranial cruciate ligament.

Methods An arthroscopic technique was used with the aim of placing the graft in an anatomically correct position to restore cranial cruciate ligament function. A retrospective collection of data was performed from the first 30 dogs treated with this technique. The clinical evaluation included stifle stability, range of motion, lameness, as well as an independent radiographic evaluation of osteoarthritis.

Results Twenty-one of the dogs were followed for 12 months after surgery and all of these were stable with negative cranial instability and pivot shift tests. Despite the promising clinical outcome, the radiographic evaluation at the final follow-up visit revealed that the pre-operative level of osteoarthritis had increased in 75% of the dogs during the first year after surgery. The complications reported were related to the use of an oversized fixation staple.

Conclusion The initial clinical results with the use of a synthetic graft for stabilization and reconstruction of a ruptured cranial cruciate ligament are promising although the fixation technique needs to be further improved.

Introduction

Rupture of the cranial cruciate ligament (CCL) is the most common cause of stifle joint lameness in dogs.^{1,2} A ruptured CCL results in an unstable joint and secondary inflammation which, over time, often leads to the development of progressive osteoarthritis (OA).^{3,4}

Numerous conventional and surgical techniques have been developed for treatment of a ruptured CCL ligament.^{3,5-7} Surgical replacement of a ruptured CCL ligament was advocated in the early 1950s, when an intra-articular technique using an autograft was presented.⁸ The technique was never widely accepted due to the challenging surgical protocol, involving the drilling of femoral and tibial bone tunnels, together with problems related to donor site morbidity and graft necrosis.⁵ Extra-articular suture techniques, as well as different osteoplasty procedures, have also been developed to address the stifle instability after a CCL rupture.^{7,9-12} One of the most frequently used osteotomies to stabilise the stifle is the tibial plateau-levelling osteotomy (TPLO).^{7,13,14}

Besides the original technique introduced by Paatsama in 1952, the surgical techniques de-

scribed above focus on treating the symptoms of CCL deficiency rather than restoring its function. Today there are no evidence-based data available to suggest one treatment over another.^{14,15}

A synthetic graft manufactured from a biocompatible, degradable polyurethaneurea (Artelon®) has previously been utilized in CCL reconstruction in rabbits and mini-pigs.¹⁶ The animals were followed for up to 24 months after surgery. The study concluded that the graft successfully restored stifle function and a histological evaluation confirmed biocompatibility of the material as well as tissue ingrowth between the fibres.¹⁶

In the present data collection the Artelon® material was used as a single-bundle CCL graft in the replacement of a ruptured CCL in clinical dogs. The graft was implanted using an intra-articular technique. However, instead of conventional open surgery, the grafts were placed using a minimally invasive arthroscopic surgical technique. The aim of this report is to describe the surgical technique and the clinical outcome for the first 30 dogs treated.

Methods

Cases

Thirty dogs received an Artelon[®] graft in replacement of a ruptured CCL. Surgical treatment was performed by a single clinician in a private practice setting in year 2008. The dogs were of mixed breeds with a mean weight of 33.5 kg (range 9 – 64) and a mean age of 56 months (range 8 – 131) at surgery (Table 1). Prior to surgery all dog owners were informed about the above treatment, as well as available alternative surgical treatments. The final decision regarding treatment was made by the dog owner and

clinician together to ensure that each dog received the best possible care.

Data collection

Clinical and radiographic data were collected retrospectively for this report from pre-treatment and follow-up visits. The clinical data were in accordance with the clinic's routines for CCL replacement, and all evaluations had been made by the treating clinician. Prior to data collection, all dog owners gave their consent to the review of their dog's medical records.

Table 1. Breed, sex, weight and age at surgery

Case	Breed	Sex	Weight (kg)	Age (years, months)
1	German Shepherd	Female	32.4	4y 4m
2	Rottweiler	Male	41.2	2y 0m
3	Mongrel	Female	26.0	8y 11m
4	Newfoundland	Female	60.0	6y 4m
5	Cairn Terrier	Female	9.1	7y 0m
6	Welsh Springer Spaniel	Male	20.9	3y 11m
7	Finnish Lapphund	Female	18.7	6y 10m
8	Riesenschnauzer	Male	30.5	8y 0m
9	Swedish Lapphund	Female	20.7	7y 0m
10	Chow Chow	Male	21.5	4y 3m
11	Chow Chow	Male	29.3	5y 0m
12	Cairn Terrier	Male	10.7	7y 0m
13	Doberman Pincher	Female	33.0	1y 3m
14	Weimaraner	Male	39.0	4y 7m
15	Labrador Retriever	Female	34.0	1y 10m
16	Briard	Male	63.5	5y 9m
17	Mongrel	Female	34.0	5y 3m
18	American Staffordshire Terrier	Female	25.0	3y 3m
18	Rottweiler	Female	45.6	1y 9m
20	Mongrel	Female	42.5	1y 2m
21	Mongrel	Male	48.0	3y 3m
22	Mongrel	Male	48.6	8y 10m
23	Midschnauzer	Female	19.5	10y 11m
24	American Bulldog	Male	40.0	2y 2m
25	Rhodesian Ridgeback	Male	43.5	8y 7m
26	Chow Chow	Male	30.0	1y 3m
27	Doberman Pincher	Female	32.0	1y 8m
28	Boxer	Female	24.5	3y 10m
29	Golden Retriever	Female	42.0	4y 5m
30	Labrador Retriever	Male	34.7	6y 7m

Clinical evaluation

The clinical data included an evaluation of stifle stability, as well as an estimation of the stifle range of motion. Stability assessments were performed while the dogs were sedated. The cranial instability of the stifle was assessed with the dog in lateral recumbency and the stifle in 30° of flexion. The test was performed by attempting to move the tibia in a cranial direction while keeping the femur in a fixed position (similar to cranial drawer). A positive test, i.e. detection of cranial movement of the tibia, was indicative of a ruptured CCL. The rotational stability of the stifle was assessed using the pivot shift test. An insufficient or ruptured CCL would result in a positive test that was characterised by abnormal internal rotation of the tibia with lateralisation of the hock, resulting in a spontaneous lateral change in direction of the stifle joint.^{14,17} The stifle range of motion was assessed subjectively using the contra-lateral stifle as reference. A clinical evaluation of lameness was also performed. Any complications related to the treatment of the ruptured CCL were documented.

Radiographic evaluation

The radiographic level of OA in the treated joint was evaluated from images taken before treatment and 12 months after surgery. The evaluation was performed by an independent and experienced radiologist using standard lateral stifle projections as described by Brunnberg et al (Table 2).¹⁸

Surgical procedure

The dogs were given a standard pre-anaesthetic drug combination consisting of 0.01-0.03 mg/kg medetomidine (Domitor vet, Orion Pharma AB, Animal Health, Sollentuna, Sweden) and 0.1-0.2 mg/kg butorphanol tartate (Dolorex vet, Intervet/Schering-Plough Animal Health, Sollentuna, Sweden) injected intra-muscularly approximately 30 minutes prior to being anaesthetised with 2-3 mg/kg propofol (PropoVet, Orion Pharma AB, Animal Health, Sollentuna, Sweden). After endotracheal intubation the dogs were maintained with sevoflurane in a standard mixture of nitrous oxide and oxygen. An S/5 ADU Carestation® anaesthesia delivery system (GE Healthcare, Madison, Wisconsin, USA) with controlled ventilation and complete surveillance was used during surgery.

Arthroscopic surgical technique

With the leg in extension, the parapatellar cranio-lateral and craniomedial arthroscopic portal positions were identified at the joint line adjacent to the lateral and medial patella tendon margins. The joint was distended by a steady flow of sterile saline (0.9% NaCl) at 40-120 mmHg. An arthroscope (Olympus Europa Holding GmbH, Hamburg, Germany) with a 30° oblique viewing angle was introduced and the native CCL tibial footprint identified. Remnants of the torn CCL were debrided, any osteophytes at risk to interfere with the graft once positioned were

Table 2. Stifle osteoarthritis (OA) score as described by Brunnberg et al.¹⁸

Grade	Description
0	No OA changes
1	Mild OA; osteophytes in the distal patella, sclerosis and osteophytes of the trochlear ridge
2	Moderate OA; osteophytes in the distal and proximal patella, sclerosis and osteophytes of the trochlear ridge, osteophytes in the area of fabella and sclerosis of the tibial plateau
3	Severe OA; the same signs as in grade 2 but of greater extent plus osteophytes in the caudal tibial plateau and sulcus of m. extensor digitorum longus

removed with a shaver, and any concomitant meniscal tears were treated by partial meniscectomy.

A drill guide (ACUFEX™ Director Comprehensive Endoscopic Drill Guide System, Smith & Nephew Inc., Memphis, Tennessee, USA) was used to direct a 2.0 mm Kirschner wire at the centre of the tibial CCL footprint (Fig. 1). The drill tunnel exit was as perpendicular to the footprint surface as possible. Aiming at the tibial footprint, the tunnel entrance was positioned < 1 cm medial to the distal extent of the tibial tuberosity. The tibial tunnel was performed by overdrilling the wire with a 4.0 mm cannulated drill (Smith & Nephew Inc., Memphis, Tennessee, USA). For large dogs the tunnel was enlarged further using 6.0 and/or 7.0 mm cannulated drills.

With the joint fully flexed, a 2.0 mm guide wire was inserted through a separate craniomedial skin incision just below the apex of the patella at the medial joint line and positioned at the centre of the femoral CCL footprint. The guide wire was then aimed at an extrasynovial exit point located at the transition zone between the condyle and femoral shaft. If this exit point could not be reached, the guide wire was driven through the supra-patellar pouch and joint. At all times during drilling a margin was maintained to the gastrocnemius sesamoid bone to avoid interference. The femoral tunnel was completed by overdrilling the guide wire with a 4.0 mm cannulated drill. Similar to the tibial tunnel, the femoral tunnel was enlarged to 6.0 or 7.0 mm as necessary. To avoid impingement of the graft a burr (Dyonics Acromionizer, Smith & Nephew Inc., Memphis, Tennessee, USA) was used to bevel the edges of the tunnels and, if needed, to perform a notchplasty to remove any osteophytes on the lateral aspect of the notch. The notchplasty was kept as small as possible. Excessive flushing was avoided prior to graft insertion to enable immediate blood soaking of the graft at insertion

Graft preparation and fixation

The Artelon® Tissue Reinforcement patch (Artimplant AB, Västra Frölunda, Sweden) was soaked in sterile saline for at least five minutes before use. The patch was then rolled up into a circular tube as a single-bundle graft with a

diameter of 4, 6 or 7 mm for small, large and very large breed dogs respectively (Fig. 2a). A graft sizing tube (ACUFEX™ Director Comprehensive Endoscopic Drill Guide System, Smith & Nephew Inc., Memphis, Tennessee, USA) was used to ensure that the desired diameter was achieved. Both ends of the graft were secured with sutures (Fig. 2b). The graft was then inserted and pulled back and forth through the bone tunnels to soak the graft in blood marrow. The graft was pulled through the femoral tunnel exit point and fixed proximally using a cobalt-chrome fixation staple (Smith & Nephew Inc., Memphis, Tennessee, USA). In very hard bone it was sometimes necessary to pre-drill holes for the staple prongs. With the graft fixed to the femur, it was stretched using a hand-held hanging scale (Kern & Sohn GmbH, Balingen, Germany). The joint was fully flexed and extended a couple of times to eliminate graft slack and the stretch load was set at 6, 8 or 9 kg for 4, 6 and 7 mm diameter grafts respectively. With the stifle in full extension, the graft was fixed distally to the tibial tunnel exit with a second fixation staple (Fig. 3). In small dogs it was sometimes necessary to trim the excess staple prong. Finally, the ends of the graft were trimmed and sutured to the surrounding periosteum to minimize mechanical irritation. The portal incision wounds were closed in separate layers using a resorbable 3-0 polyglactin suture (Vicryl, Ethicon Inc., Somerville, NJ, USA).

Postoperative care

The dogs were released from the clinic on the day of surgery. An intramuscular dose of analgesics, 0.33 mg/kg Methadone (Metadon Recip, Recip AB, Sollentuna, Sweden), was administered immediately postoperatively. A non-steroid, anti-inflammatory drug (NSAID) was recommended to reduce postoperative pain at home. An oral prophylactic antibiotic, 25-30 mg/kg Cefalexin (Kefavet, Orion Pharma AB, Animal Health, Sollentuna, Sweden) was prescribed twice daily for 10 to 15 days. No mobility restrictions were utilized. The owners were instructed to avoid walks for the first three days and to use a leash during walks for the first four to six weeks.

Figure 1. The centre of the tibial footprint (A) can be reached by aiming at its caudal edge. The tunnel should exit perpendicularly to the footprint surface. The tunnel entrance (B) should be positioned < 1 cm medial to the distal extent of the tibial tuberosity.

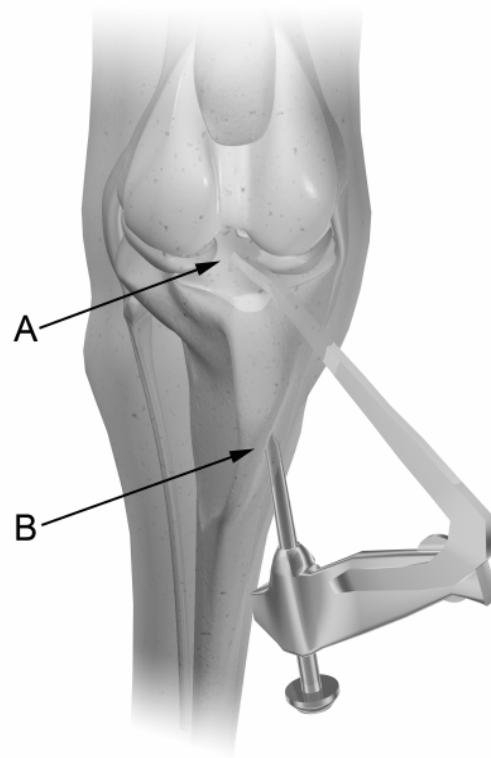
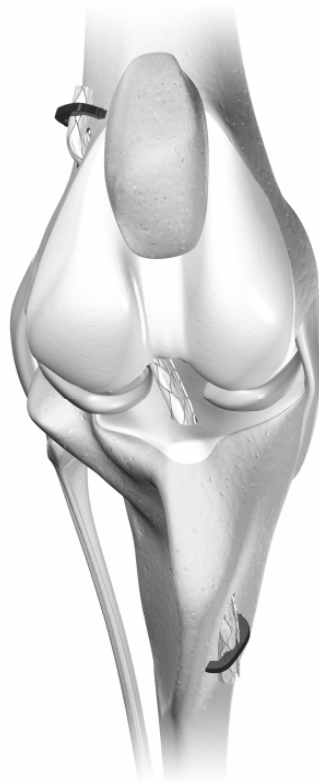

Figure 2. The synthetic CCL patch was rolled into a circular tube and both ends were secured with baseball stitches using USP #0 absorbable sutures (A). USP #2 hold sutures were attached at each end and a double stitch was made at one end according to the figure (B).




Figure 3. Femoral and tibial tunnel placements and orientation of the fixation staples.



Results

All dogs were lame and clinically unstable prior to surgery. Two dogs had undergone previous surgery with replacement of the ruptured CCL with allografts although both repairs had failed.

The dogs were scheduled for an initial follow-up visit at two months after surgery. Clinical data were available from 24 dogs (80%) that attended the visit. One dog had a slightly positive pivot shift and another two dogs presented with positive cranial instability tests. The remaining stifles were stable. The majority of dogs ($n = 22$) had the same range of motion as the contralateral stifle. All but three dogs were clinically lame. One year after surgery 21 dogs (70%) attended their scheduled follow-up visit. Five dogs failed to attend the visit due to poor owner compliance and four dogs were euthanized prior to the visit for reasons unrelated to the CCL replacement. All dogs attending the visit were stable with negative cranial instability and pivot shift tests. A 10% decrease in range of motion was reported

in four dogs and a 20% decrease in five dogs. Seven of these nine dogs had meniscal damage prior to treatment. In 16 dogs (76%) the lameness had completely resolved at the 12-month visit.

The radiographic evaluation revealed that the majority of dogs (70%) had already developed some degree of OA in the affected joint prior to surgery. A total of four dogs were classified with OA grade I, eight dogs were classified with OA grade II and two dogs were classified with OA grade III. At the final follow-up the level of OA in the treated joints had increased in 15 dogs and remained unchanged in 5 dogs (Fig. 4).

Over time, it became apparent that the fixation staples were interfering with the surrounding soft tissue, causing mechanical irritation, crepitus and/or pain in 12 of the 30 treated dogs. During a second surgery (open procedure) at the 12-month visit the staples causing irritation were either removed ($n = 9$) or the prongs were shortened

flush to the bone (n = 3) with the use of a pin cutter (Super Bite Pin Cutter, Smith & Nephew Inc., Memphis, Tennessee, USA). After the staples had either been removed or shortened, the owners reported their dogs to be free of pain and any crepitus or lameness had been resolved. Although no longer clinically lame, two of the dogs suffered from temporary periods of stiffness following vigorous exercise. The owners reported that the stiffness resolved with rest and a low dose of over-the-counter NSAIDs.

Discussion

The described treatment for CCL replacement combines anatomical placement of a synthetic graft using a minimally invasive arthroscopic surgical technique. The signalment of the 30 dogs treated was similar to what has been previously described in the literature for dogs treated for CCL rupture with regard to breed, weight, age, gender and presence of pre-operative OA.^{3,19-24} The aim of the described treatment was, as with other surgical treatment

alternatives available today, to achieve pain relief, restore stifle function and stability, and minimise the progression of OA. A dog undergoing TPLO surgery or any other osteotomy is subjected to major trauma and as such the postoperative pain management is a substantial part of the rehabilitation process. In addition, any osteotomy is associated with a strict rehabilitation period during recovery, allowing for the bone to heal. The dog needs to be hospitalised for two to five days and the return to function is not expected until 10 to 12 weeks after surgery.^{23,24} An arthroscopic technique minimises the surgical trauma compared to conventional open arthrotomy. By using an arthroscopic technique in CCL repair or replacement the dog can return to function within four to six weeks.²⁵ The present treatment was performed on an out-patient basis, where the dog was allowed to return home on the day of surgery. The initial dose of methadone for immediate postoperative pain management was replaced by oral NSAIDs administered at the owner's discretion when the dog returned home.

Figure 4. The change in grade of radiographic osteoarthritis during the first year after surgery.

12-month follow-up

		Grade				
		0	1	2	3	
Pre-operative	0	0	2	4	0	6
	1	0	1	2	1	4
	2	0	0	2	6	8
	3	0	0	0	2	2
		0	3	8	9	20

All but three dogs with CCL reconstruction using a synthetic graft achieved complete rotational and translational stability in their affected stifle immediately after surgery. The three initially unstable dogs achieved complete stability within six months after surgery. It might be argued that the stabilization in these cases resulted from postoperative periarticular fibrosis. However, stabilization by periarticular fibrosis have previously been reported in association with decreased range of motion.²⁶ When finally stabilized, the dogs treated with the present surgical technique did not show any signs of limited range of motion of the stifle.

One of the goals when stabilising the joint is to minimize or slow the radiographic progression of OA.²⁷ The evaluation of the radiographs from treated dogs was made using a classification system that was straightforward, but still provided sufficient details to identify changes over time.¹⁸ The diversity of radiographic classification and scoring systems used today makes it difficult to compare the progression of OA in different studies.^{18,21} In addition, the above systems are based on the assessment of periarticular osteophyte formation and since osteophytes are routinely removed at surgery, this will inevitably have an impact on postoperative assessments.

Although stabilisation of the joint was successfully achieved in all cases at the 12-month visit, the radiographic evaluation revealed an increase of the OA grade in the majority of dogs (75%). This is in accordance with previous reports of other frequently used surgical treatments, i.e. TPLO and different types of extracapsular techniques.^{21,28-30} In recent years a combination of biomechanical and biologic factors has been suggested to cause CCL deficiency, subsequent ligament rupture and development of OA.^{1,4} This could to some extent explain the progression of OA seen in radiographs of the dogs that have been surgically stabilized and have clinically functional stifle joints. This lack of relationship between the

radiographic and clinical outcome after CCL reconstruction has been previously reported.^{3,31}

Complication rates between 12% and 28% have been reported in studies related to osteotomies and extracapsular techniques.^{19,20,22,23,29} Frequently occurring complications include tibial tuberosity fractures or avulsions, patellar tendonitis, meniscal injuries, and infections or problems related to the implants used. Although the complication rate in this retrospective evaluation was 40%, the complications reported were all related to the fixation staples. In some cases the prongs of the staples penetrated the femoral and/or tibial bones resulting in interference with the surrounding soft tissue, causing mechanical irritation, crepitus and subsequent lameness. In three dogs the staple prongs were shortened and in nine dogs the staples were removed during a second surgical session in conjunction with the 12-month postoperative visit. After the second surgery the lameness was resolved in all dogs. In the future, a second surgery might be avoided by using a different fixation technique.

The presented data were retrospectively collected from a rather small number of dogs. Also, the clinical evaluations were subjective and made by the treating clinician. This should be considered when interpreting the results. Nevertheless, the experience from the first 30 dogs treated with a synthetic graft in replacement of a ruptured CCL has been encouraging. Although the fixation technique needs to be further improved, the lameness had resolved and the joint was stable in all dogs followed for one year after surgical treatment.

Acknowledgments

The author gratefully acknowledges Dr. Lars Gustafson, DVM, for the radiographic evaluation and Ann-Britt Abrahamsson for valuable administrative assistance.

References

1. de Rooster H, de Bruin T, van Bree H. Morphologic and functional features of the canine cruciate ligaments. *Vet Surg* 2006; 35: 769-80.
2. Harasen G. Canine cranial cruciate ligament rupture in profile: 2002-2007. *Can Vet J* 2008; 49: 193-4.
3. Vasseur PB. Clinical results following non-operative management for rupture of the cranial cruciate ligament in dogs. *Vet Surg* 1984; 13: 243-6.
4. Cook JL. Cranial cruciate ligament disease in dogs: Biology versus biomechanics. *Vet Surg* 2010; 39: 270-7.
5. Arnoczky SP. BSAVA EDUCATION COMMITTEE COMMISSIONED ARTICLE. The cruciate ligaments: the enigma of the canine stifle. *J Small Anim Pract* 1988; 29: 71-90.
6. Banwell MN. In vitro evaluation of the securos cranial cruciate ligament repair system and fluorocarbon leader line for use as lateral fabella-tibial sutures. Thesis 2004. Louisiana State University, Baton Rouge.
7. Kim SE, Pozzi A, Kowaleski MP, Lewis DD. Tibial osteotomies for cranial cruciate ligament insufficiency in dogs. *Vet Surg* 2008; 37: 111-25.
8. Paatsama S. Ligament injuries in the canine stifle joint. A clinical and experimental study. Thesis 1952. University of Helsinki, Helsinki.
9. Childers HE. New method for cruciate ligament repair II. Repair by suture technique. *Mod Vet Pract* 1966; 47: 59-60.
10. DeAngelis M, Lau RE. A lateral retinacular imbrication technique for the surgical correction of anterior cruciate ligament rupture in the dog. *J Am Vet Med Assoc* 1970; 157: 79-84.
11. Pearson P, McCurrin D, Carter J, Hoskins J. Lembert suture technique to surgically correct ruptured cruciate ligaments. *J Am Anim Hosp Assoc* 1971; 7: 1-13.
12. Flo G. Modification of the lateral retinacular imbrication technique for stabilizing cruciate ligament injuries. *J Am Anim Hosp Assoc* 1975; 11: 570-6.
13. Slocum B, Slocum TD. Tibial plateau leveling osteotomy for repair of cranial cruciate ligament rupture in the canine. *Vet Clin North Am Small Anim Pract* 1993; 23: 777-95.
14. Boudrieau RJ. Tibial plateau leveling osteotomy or tibial tuberosity advancement? *Vet Surg* 2009; 38: 1-22.
15. Aragon CL, Budberg SC. Applications of evidence-based medicine: cranial cruciate ligament injury repair in the dog. *Vet Surg* 2005; 34: 93-8.
16. Liljensten E, Gisselbalt K, Edberg B, Bertilsson H, Flodin P, Nilsson A, Lindahl A, Peterson L. Studies of polyurethane urea bands for ACL reconstruction. *J Mater Sci Mater Med* 2002; 13: 351-9.
17. Galway RD, Beaupré A, MacIntosh DL. Pivot Shift: A clinical sign of symptomatic anterior cruciate insufficiency. *J Bone Joint Surg* 1972; 54B: 763-4.
18. Brunnberg L, Rieger I, Hesse EM. 7 years experience with modified over-the-top cruciate ligament plastic operation in dog. *Kleinterpraxis* 1992; 37: 735-46.
19. Pacchiana PD, Morris E, Gillings SL, Jessen CR, Lipowitz AJ. Surgical and postoperative complications associated with tibial plateau leveling osteotomy in dogs with cranial cruciate ligament rupture: 397 cases (1998-2001). *J Am Vet Med Assoc* 2003; 222: 184-93.
20. Priddy NH 2nd, Tomlinson JL, Dodam JR, Hornbostel JE. Complications with and owner assessment of the outcome of tibial plateau leveling osteotomy for treatment of cranial cruciate ligament rupture in dogs: 193 cases (1997-2001). *J Am Vet Med Assoc* 2003; 222: 1726-32.
21. Lazar TP, Berry CR, deHaan JJ, Peck JN, Correa M. Long-term radiographic comparison of tibial plateau leveling osteotomy versus extracapsular stabilization for cranial cruciate ligament rupture in the dog. *Vet Surg* 2005; 34: 133-41.
22. Stauffer KD, Tuttle TA, Elkins AD, Wehrenberg AP, Character BJ. Complications associated with 696 tibial plateau leveling osteotomies (2001-2003). *J Am Anim Hosp Assoc* 2006; 42: 44-50.
23. Cook JL, Luther JK, Beetem J, Karnes J, Cook CR. Clinical comparison of a novel extracapsular stabilization procedure and tibial plateau leveling osteotomy for treatment of cranial cruciate ligament deficiency in dogs. *Vet Surg* 2010; 39: 315-23.
24. Fitzpatrick N, Solano MA. Predictive variables for complications after TPLO with stifle inspection by arthrotomy in 1000 consecutive dogs. *Vet Surg* 2010; 39: 460-74.
25. Hoelzler MG, Millis DL, Francis DA, Weigel JP. Results of arthroscopic versus open arthrotomy for surgical management of cranial cruciate ligament deficiency in dogs. *Vet Surg* 2004; 33: 146-53.

26. Budsberg SC, Verstraete MC, Soutas-Little RW, Flo GL, Probst CW. Force plate analyses before and after stabilization of canine stifles for cruciate injury. *Am J Vet Res* 1988; 49: 1522-4.
27. Slocum B, Slocum TD. Tibial plateau leveling osteotomy for cranial cruciate ligament rupture. In: *Current techniques in small animal surgery*. (Ed.) (Eds.) Bojrab, M.J. Williams & Wilkins, Baltimore, MD, 1998; pp. 1209-1215
28. Boyd DJ, Miller CW, Etue SM, Monteith G. Radiographic and functional evaluation of dogs at least 1 year after tibial plateau leveling osteotomy. *Can Vet J* 2007; 48: 392-6.
29. Kunkel KA, Basinger RR, Suber JT, Gerard PD. Evaluation of a transcondylar toggle system for stabilization of the cranial cruciate deficient stifle in small dogs and cats. *Vet Surg* 2009; 38: 975-82.
30. Au KK, Gordon-Evans WJ, Dunning D, O'Dell-Anderson KJ, Knap KE, Griffon D, Johnson AL. Comparison of short- and long-term function and radiographic osteoarthritis in dogs after postoperative physical rehabilitation and tibial plateau leveling osteotomy or lateral fabellar suture stabilization. *Vet Surg* 2010; 39: 173-80.
31. Gordon WJ, Conzemius MG, Riedesel E, Besancon MF, Evans R, Wilke V, Ritter MJ. The relationship between limb function and radiographic osteoarthritis in dogs with stifle osteoarthritis. *Vet Surg* 2003; 32: 451-4.

Correspondence

Krister Julinder, DVM

Söderköpings Djurklinik, Artrokliniken, Ringvägen 40, SE-614 31 Söderköping, Sweden

E-mail: animalartroclinic@telia.com